

PYFS Anatomy Review

THE ANATOMICAL MALE MUSCULAR SYSTEM

Key: Muscles of Anterior Torso

- Subclavius m.
- External intercostal m.
- External intercostal m. (superior layer)
- External intercostal m. (middle layer)
- External intercostal m. (inferior layer)
- Rectus abdominis m.
- External abdominal oblique m.
- Internal abdominal oblique m.
- Transversus abdominis m.
- Transversus abdominis m. (superior part)
- Transversus abdominis m. (inferior part)
- Transversus abdominis m. (medial part)
- Transversus abdominis m. (lateral part)
- Transversus abdominis m. (medial part)
- Transversus abdominis m. (lateral part)

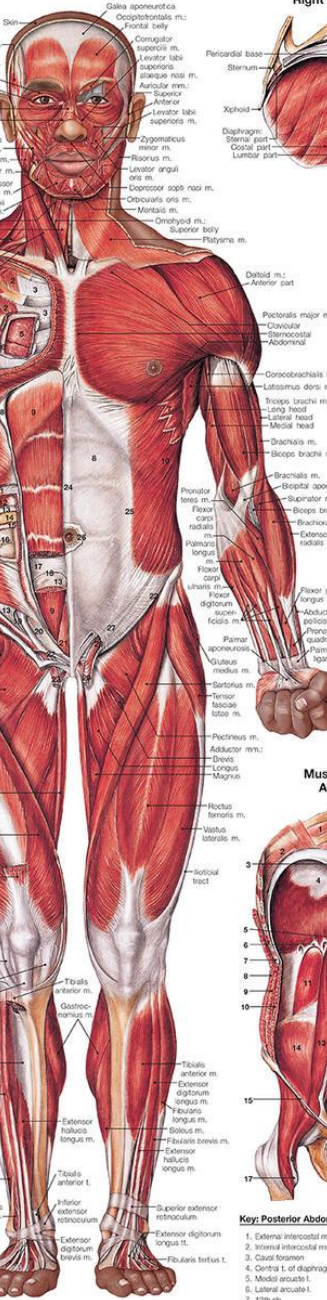
15. Pectoralis major m.
16. Latissimus dorsi m.
17. Rectus abdominis m.
18. External intercostal m.
19. External intercostal m.
20. External intercostal m.
21. External intercostal m.
22. External intercostal m.
23. External intercostal m.
24. External intercostal m.
25. External intercostal m.
26. External intercostal m.
27. External intercostal m.
28. External intercostal m.
29. External intercostal m.
30. External intercostal m.

- ### Muscles of Right Hand (Palmar View)
1. Flexor carpi radialis m.
 2. Flexor carpi ulnaris m.
 3. Flexor digitorum profundus m.
 4. Flexor digitorum superficialis m.
 5. Flexor pollicis longus m.
 6. Flexor pollicis longus m.
 7. Flexor pollicis longus m.
 8. Flexor pollicis longus m.
 9. Flexor pollicis longus m.
 10. Flexor pollicis longus m.

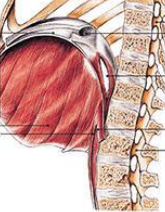- ### Key: Muscles of Right Hand
1. Flexor carpi radialis m.
 2. Flexor carpi ulnaris m.
 3. Flexor digitorum profundus m.
 4. Flexor digitorum superficialis m.
 5. Flexor pollicis longus m.
 6. Flexor pollicis longus m.
 7. Flexor pollicis longus m.
 8. Flexor pollicis longus m.
 9. Flexor pollicis longus m.
 10. Flexor pollicis longus m.

- ### Key: Abbreviations
- Ligament—L
 - Ligament—L
 - Muscle—m.
 - Muscle—mm.
 - Tendon—t.
 - Tendon—t.
 - Tendon—t.
 - Tendon—t.
 - Tendon—t.
 - Tendon—t.

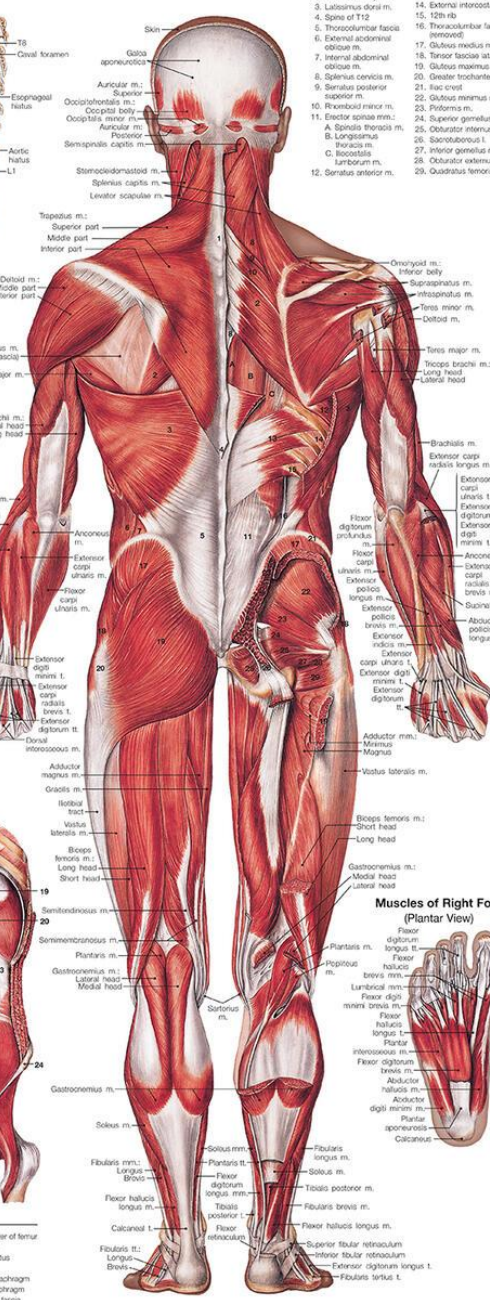
Anterior View



Right Half of Diaphragm



Posterior View



Key: Muscles of Posterior Torso

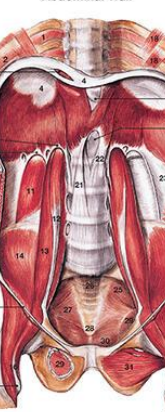- Spine of C7
- Rhomboid major m.
- Latissimus dorsi m.
- Spine of T12
- Thoracolumbar fascia
- External abdominal oblique m.
- Serratus posterior superior m.
- Serratus posterior inferior m.
- Rhomboid minor m.
- Serratus anterior m.
- Erector spinae m.
- Spina thoracis m.
- Longissimus thoracis m.
- Spinae m.
- Serratus anterior m.

13. Serratus posterior inferior m.
14. External intercostal m.
15. 12th rib
16. Thoracolumbar fascia
17. External abdominal oblique m.
18. Tensor fasciae latae m.
19. Gluteus maximus m.
20. Greater trochanter
21. Iliac crest
22. Gluteus minimus m.
23. Piriformis m.
24. Superior gemelli m.
25. Obturator internus m.
26. Longissimus thoracis m.
27. Inferior gemelli m.
28. Obturator externus m.
29. Quadratus femoris m.

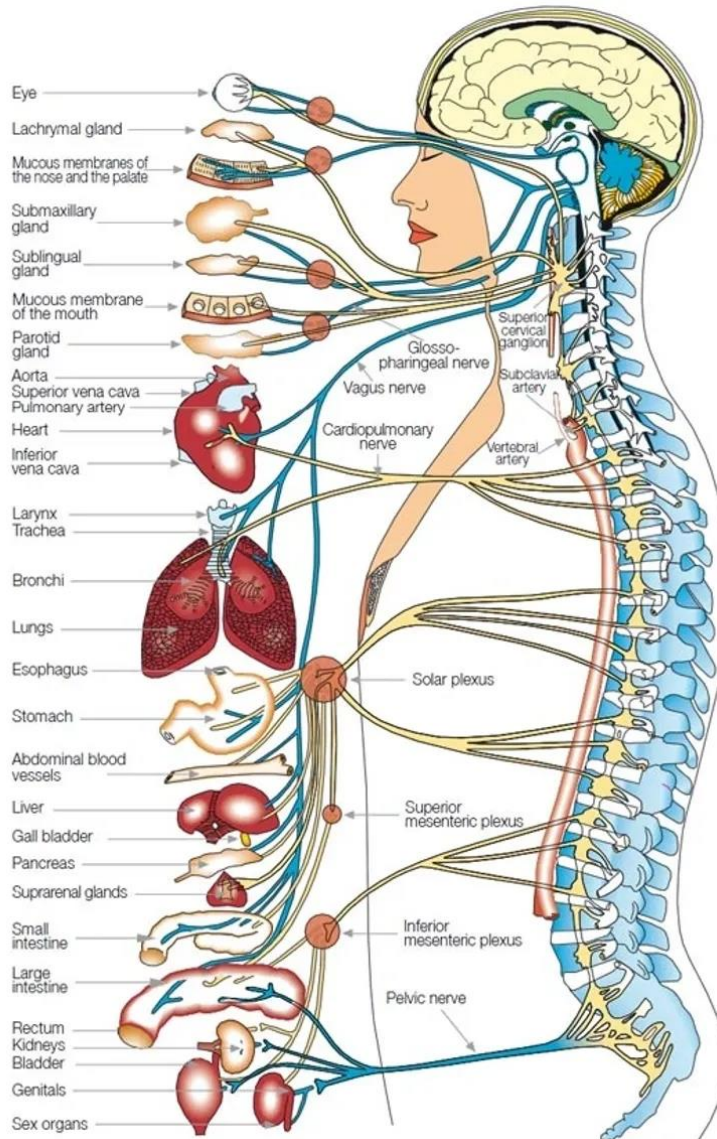
- ### Muscles of Right Foot (Plantar View)
1. Flexor digitorum profundus m.
 2. Flexor digitorum superficialis m.
 3. Flexor hallucis longus m.
 4. Flexor hallucis longus m.
 5. Flexor hallucis longus m.
 6. Flexor hallucis longus m.
 7. Flexor hallucis longus m.
 8. Flexor hallucis longus m.
 9. Flexor hallucis longus m.
 10. Flexor hallucis longus m.

- ### Key: Muscles of Right Foot
1. Flexor digitorum profundus m.
 2. Flexor digitorum superficialis m.
 3. Flexor hallucis longus m.
 4. Flexor hallucis longus m.
 5. Flexor hallucis longus m.
 6. Flexor hallucis longus m.
 7. Flexor hallucis longus m.
 8. Flexor hallucis longus m.
 9. Flexor hallucis longus m.
 10. Flexor hallucis longus m.

Muscles of Posterior Abdominal Wall

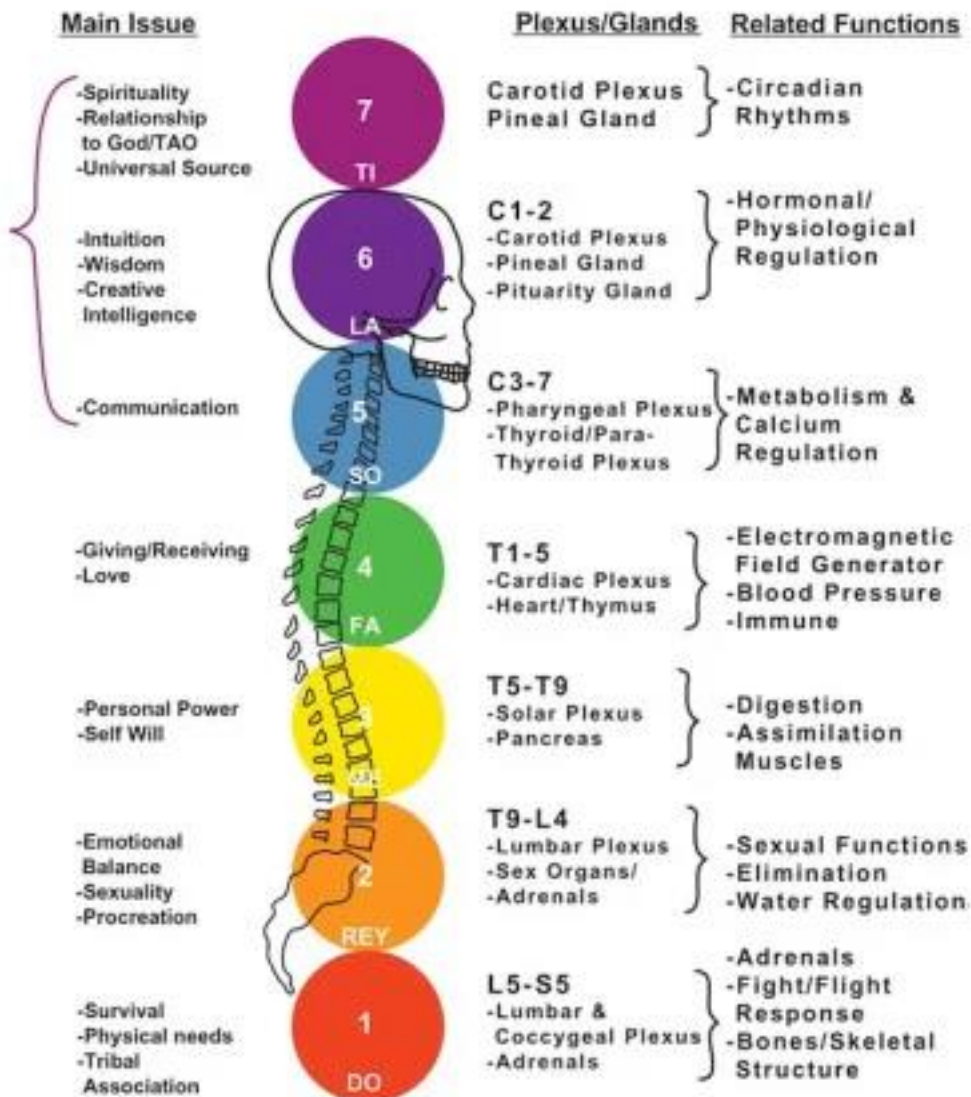


- ### Key: Posterior Abdominal Muscles
1. External intercostal m.
 2. Internal intercostal m.
 3. Costal foramen
 4. Central l. of diaphragm
 5. Medial arcuate l.
 6. Lateral arcuate l.
 7. 12th rib
 8. External abdominal oblique m.
 9. Internal abdominal oblique m.
 10. Transversus abdominis m.
 11. Quadratus lumborum m.
 12. Psoas minor m.
 13. Psoas major m.
 14. Sacrum m.
 15. Iliac crest
 16. Iliopsoas m.
 17. Lesser trochanter of femur
 18. Subclavius m.
 19. Esophageal hiatus
 20. Aortic hiatus
 21. Right crus of diaphragm
 22. Left crus of diaphragm
 23. Thoracolumbar fascia
 24. Anterior superior iliac spine
 25. Piriformis m.
 26. Sacrum
 27. Coccygium
 28. Coccyx
 29. Obturator internus m.
 30. Levator ani m.
 31. Obturator externus m.



VERTEBRAE	AREAS AND PARTS OF THE BODY	POSSIBLE SYMPTOMS
CERVICAL		
C 1	• Back of the head	Headaches (including migraines, aches or pain at the back of the head, behind the eyes or in the forehead, throbbing or pulsating discomfort at the top or back of head)
C 2	• Various areas of the head	
C 3	• Side and front of the neck	
C 4	• Upper back of the neck	Jaw muscle, or joint aches or pains
C 5	• Middle of neck and upper part of arms	
C 6	• Lower part of neck, arms and elbows	Dizziness, nervousness, vertigo
C 7	• Lower part of arms, shoulders	Soreness, tension and lightness felt in back of neck and throat area
DORSAL		
D 1	• Hands, wrists, fingers, thyroid	Pain, soreness, and restriction in the shoulder area
D 2	• Heart, its valves and coronary arteries	Bursitis, tendonitis
D 3	• Lungs, bronchial tubes, pleura, chest	Pain and soreness in arms, hands, elbows and/or fingers
D 4	• Gall bladder, common duct	
D 5	• Liver, solar plexus	Chest pains, tightness or constriction, asthma, difficulty breathing
D 6	• Stomach, mid-back area	Middle or lower mid-back pain, discomfort and soreness
D 7	• Pancreas, duodenum	Various and numerous symptoms from trouble or malfunctioning of:
D 8	• Spleen, lower mid-back	- Thyroid
D 9	• Adrenal glands	- Heart
D 10	• Kidneys	- Lungs
D 11	• Ureters	- Gall bladder
D 12	• Small intestine, upper/lower back	- Liver
		- Stomach
		- Pancreas
		- Spleen
		- Adrenal glands
		- Kidneys
LUMBAR		
L 1	• Iliocolic valve, large intestine	- Small and large intestines
L 2	• Appendix, abdomen, upper leg	- Six organs
L 3	• Sex organs, uterus, bladder, knees	- Uterus
L 4	• Prostate gland, lower back	- Bladder
L 5	• Sciatic nerve, lower legs, ankles, feet	- Prostate glands
		Low back pain, aches and soreness
		Trouble walking
		Leg, knee, ankle and foot soreness and pain
SACRO		
	• Hip bones, buttocks	Sciatica, pain or soreness in the hip and buttocks
COXIS		
	• Rectum, anus	Rectal trouble

Figure 13



Consider checking out these apps:

- Complete Anatomy
- Visual Anatomy Lite
- 3D Anatomy Learning
- Pocket Anatomy
- 3D Yoga Anatomy

Download the Anatomy Review Workbooks